

Cadaveric Study of the Adult Human Brachial Artery

Dipti A. Nimje*, Harish A. Wankhede**, P.B. Hosmani***, M.M. Baig****

Abstract

Background: The brachial artery lies immediately deep to the deep fascia. Various variations of the brachial artery and its branches are quoted in literature. Prior anatomical knowledge of such anomalies may be of great clinical significance. The present study concentrates on the morphological features of the brachial artery. **Methodology:** The study was done by the dissection method on 70 human brachial arteries from 35 embalmed human cadavers from various medical colleges in Maharashtra. **Results:** The brachial artery was found to be originating as the continuation of the axillary artery below the lower border of teres major. The mean length of the brachial artery on right side was 24.91 ± 4.13 cm and on left side was 25.27 ± 3.79 cm. On right side mean diameter of the brachial artery at origin was 0.54 ± 0.06 cm and above termination was 0.50 ± 0.06 cm and on left side mean diameter at origin was 0.52 ± 0.05 cm and above termination was 0.49 ± 0.06 cm. The level of termination of the brachial artery above the inter-condylar line was seen in 2 specimens (5.71%) on right side and in 1 specimen (2.85%) on left side and below the inter-condylar line in 33 specimens (94.28%) on right side and in 34 specimens (97.14%) on left side. The presence of the superficial brachial artery was most common variation found in the brachial artery (7.14%), next common variation was higher termination (4.28%). The accessory brachial artery seen in only 1 specimen (1.42%). **Conclusion:** Anatomical knowledge of brachial artery is important because it is commonly used for various surgical and interventional procedures.

Keywords: Axillary Artery; Accessory Brachial Artery; Brachial Artery; Higher Termination; Superficial Brachial Artery.

Introduction

The brachial artery is the continuation of the axillary artery, the change in name occurring at the lower border of the teres major muscle. The artery is superficial in its course in the arm, lying immediately deep to the deep fascia of the anteromedial aspect of the arm. It passes deeply into the cubital fossa before dividing into the radial and ulnar arteries, usually at the level of the neck of the radius[1]. As quoted in the

literature the length of the brachial artery varies with the site of division, ranging from 15 to 30 cm, its diameter is around 0.5 to 0.6 cm[2]. Major variations of the principal arteries of the upper limb have long received the attention of anatomists. Various variations of the brachial artery and its branches are quoted in literature like superficial brachial artery, accessory brachial artery, double brachial artery, higher division of the brachial artery, superficial radial artery, aberrant radial artery, superficial ulnar artery and rarely superficial median artery[3]. Brachial artery in its upper part may also give rise to subscapular and posterior circumflex humeral artery, normally branches of the axillary artery; in its lower part to the radial recurrent artery and at its bifurcation to the interosseous artery or to median artery which is usually a branch of interosseous artery[4].

The arteries of the upper limbs are situated in a deep plane and are the favorable sites for intra-arterial cannulation[5]. Dimensions of the brachial artery and flow mediated dilatation are associated with severity

Author's Affiliation: *Assistant Professor, Department of Anatomy, Dr. Bhausaheb Hire Memorial Government Medical College, Dhule. **Assistant Professor, Department of Anatomy, Government Medical College, Miraj. ***Associate Professor, ****Professor & Head, Department of Anatomy, Vaishampayan Memorial Government Medical College, Solapur.

Corresponding Author: Dipti A. Nimje, Assistant Professor in Department of Anatomy, Dr. Bhausaheb Hire Memorial Government Medical College, Dhule, Maharashtra 424001.

E-mail: dr.dipti342@gmail.com

of cardiovascular diseases. Non invasive brachial artery analysis has useful approach for detailed study of cardiovascular system and impact of cardiovascular diseases[6].

Considering the higher incidence of anatomical variations of arteries of the upper limb, prior anatomical knowledge of such anomalies may be of great clinical significance to vascular and plastic surgeons, orthopaedicians and interventional radiologists. The presence of variations in the arterial pattern of the arm and forearm has to keep in mind during surgical procedures, at times of accidents and crush injuries and also in diagnostic procedures like cardiac catheterization, arterial grafting and other angiographic procedures. So the present morphological study intends to establish the frequency and patterns of variation for the human adult brachial arteries of the upper limb.

Material and Methods

The study was done in 70 human brachial arteries from 35 embalmed human cadavers from various medical colleges in Maharashtra by method given in Cunningham's manual of practical anatomy of upper limb [7].

The length of the brachial artery was measured using measuring tape between following points:

- At point of inferior border of the teres major muscle
- At the point of termination of brachial artery

The external diameters of the brachial artery were measured by Vernier caliper at

- Its origin
- Its termination

The variations in the brachial artery were also noted and photographed and result were analysed statistically.

Results

Following observations and results we obtained in the present study. Among all 70 specimen studied,

the brachial artery was found to be originating as the continuation of the axillary artery below the lower border of teres major (Table 1). Statistically variations in length of the brachial artery are not uniform (Chi-square value on right side=51.71, 'p' < 0.01; highly significant and on left side=52.28, 'p' < 0.01; highly significant). The mean length of the brachial artery on right side was 24.91cm with standard deviation of 4.13 and on left side was 25.27cm with standard deviation of 3.79. The maximum length of the brachial artery was found to be 29.2cm on right side and 30cm on left side. The minimum length was found to be 8cm on right side and 6cm on left side. The unpaired t-test was applied comparing the mean length of right and left sides and was found to be non significant (t-test value=0.37, df=68, 'p' > 0.05) (Table 2).

Unpaired t-test was applied for comparing mean diameter at origin of right and left sides and was found to be non significant (t value = 1.49, df=68, 'p' > 0.05). The unpaired t-test was applied for comparing mean diameter above termination of right and left sides and was found to be non significant (t-test value=0.68, df=68, 'p' > 0.05) (Table 3).

Z-test was applied for difference between two proportions i.e. level of termination above the intercondylar line on right and left sides and was found to be non significant (Z test=0.59, 'p' > 0.05). Similarly, Z-test was applied for difference between two proportions i.e. level of termination below the intercondylar line on right and left sides and was found to be non significant (Z test=0.59, 'p' > 0.05) (Table 4).

Statistically, variations in the brachial artery were found to be non uniform (Chi-square value on right side=87.14, 'p' < 0.01; highly significant and for left side Chi-square value =112, 'p' < 0.01; highly significant). The Z-test was applied for difference between two proportions i.e. normal brachial artery on right and left sides and was found to be non significant (Z test=1.07, 'p' > 0.05). Similarly for superficial brachial artery on right and left sides the test was found to be non significant (Z test=0.16, 'p' > 0.05), for higher termination of brachial artery on right and left sides was found to be non significant (Z test=0.59, 'p' > 0.05), for accessory brachial artery on right and left sides the test was found to be non significant (Z test=1.007, 'p' > 0.05) (Table 5).

Table 1: Origin of the brachial artery

Origin of brachial artery	Right		Left	
	Specimens	Percentage	Specimens	Percentage
Continuation of axillary artery	35	100%	35	100%
Other type of origin	0	0%	0	0%

Table 2: Length of the brachial artery

Length of the Brachial artery in cm	Right		Left	
	Specimens	Percentage	Specimens	Percentage
5.1-10	1	2.85%	1	2.85%
10.1-15	1	2.85%	0	0%
15.1-20	0	0%	0	0%
20.1-25	11	31.42%	13	37.14%
25.1-30	22	62.85%	21	60%
Total	35	100%	35	100%
Mean±SD length	24.91±4.13		25.27±3.79	

*Chi-square test value on right side=51.71, df=4, p<0.01 (highly significant); Chi-square test value on left side=52.28, df=4, p<0.01 (highly significant)

† t-test=0.37, df=68, p>0.05 (not significant)

Table 3: Diameter of the brachial artery

Diameter of the brachial artery in cm		Mean ± S.D.	Maximum	Minimum
At origin	Right	0.54±0.06	0.8	0.38
	Left	0.52±0.05	0.62	0.42
Above termination	Right	0.50±0.06	0.67	0.35
	Left	0.49±0.06	0.66	0.41

*t-test value for diameter at origin=1.49, df=68, p>0.05 (not significant); t-test value for diameter above termination=0.68, df=68, p>0.05 (not significant)

Table 4: Variation in the level of termination of the brachial artery

Level of termination	Right		Left	
	Specimens	Percentage	Specimens	Percentage
Above inter-condylar line	2	5.71%	1	2.85%
At inter-condylar line	0	0%	0	0%
Below inter-condylar line	33	94.28%	34	97.14%

*Z-test value for termination above inter-condylar line=0.59, p>0.05 (not significant); Z-test value for termination below inter-condylar line=0.59, p>0.05 (not significant).

Table 5: Variations in the brachial artery

Variations in brachial artery	Right		Left	
	Specimen	Percentage	Specimen	Percentage
Normal pattern	29	82.85%	32	91.42%
Superficial brachial artery	3	8.57%	2	5.71%
Higher termination	2	5.71%	1	2.85%
Accessory brachial artery	1	2.85%	0	0%
Total	35	100%	35	100%

*Chi-square test value on right side=87.14, df=4, p<0.01 (highly significant); Chi-square test value on left side=112, df=4, p<0.01 (highly significant)

†Z-test value for normal brachial artery=1.07, p>0.05 (not significant)

‡Z-test value for superficial brachial artery=0.16, p>0.05 (not significant)

§Z-test value for higher termination of brachial artery=0.59, p>0.05 (not significant)

|| Z-test value for accessory brachial artery=1.007, p>0.05 (not significant)

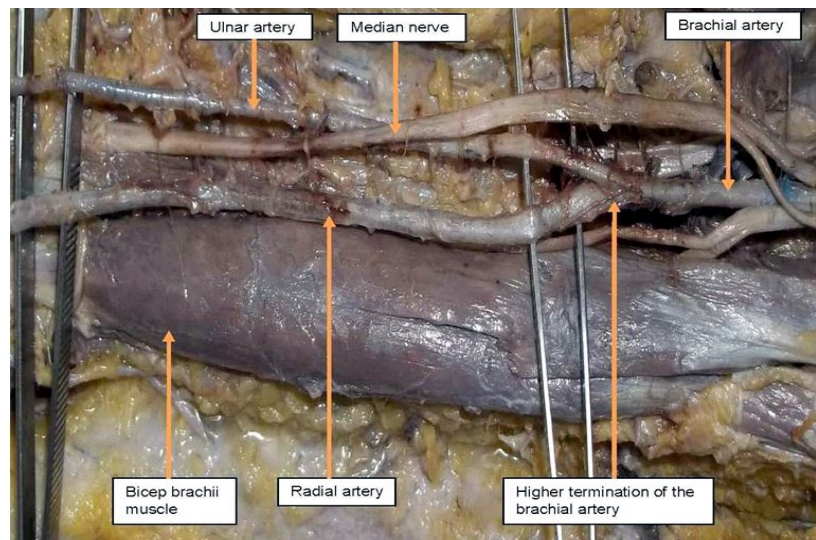


Fig. 1: Photograph showing the higher termination of the brachial artery into ulnar and radial artery which has higher origin in left arm

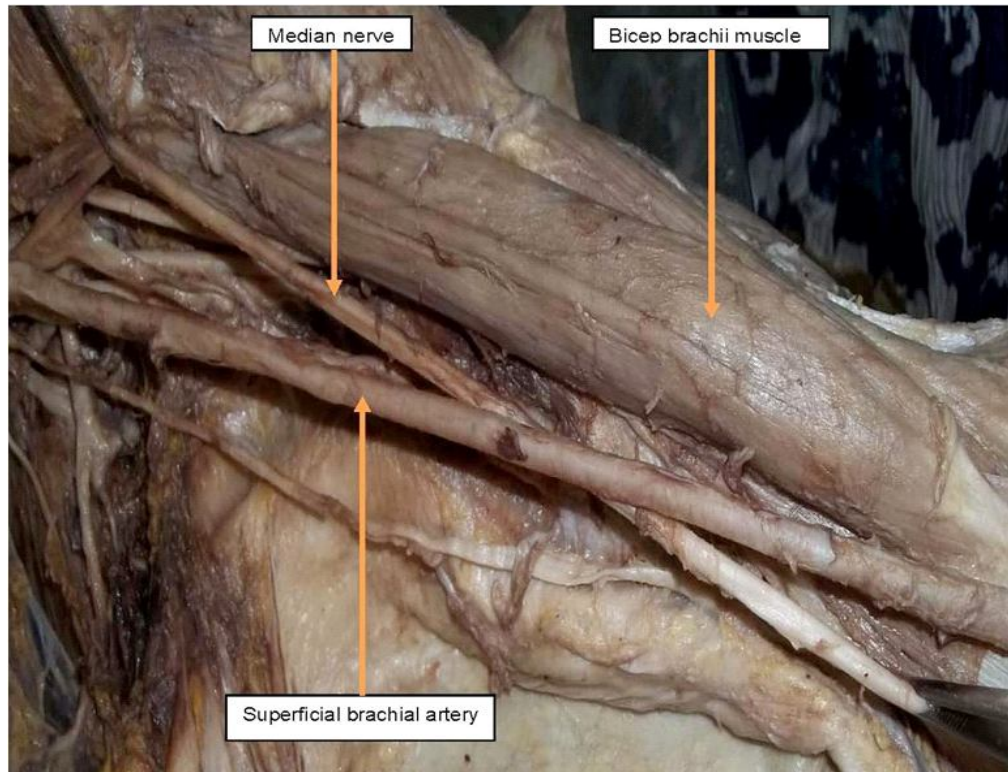


Fig. 2: Photograph showing the superficial brachial artery passing superficial to the median nerve in left arm

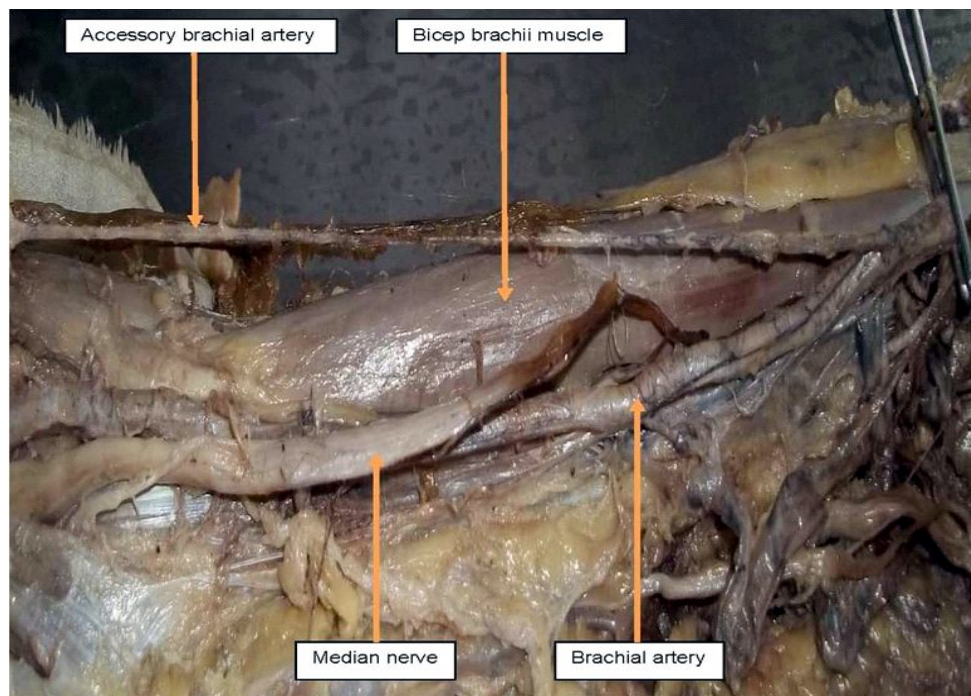


Fig. 3: Photograph showing the accessory brachial artery arising from the brachial artery in right arm. Main brachial artery divides into the ulnar and radial artery while the accessory brachial artery lies superficial to median nerve and gets terminated just below the elbow by giving small branches to forearm muscles

Discussion

For a number of reasons, anomalies of the forelimb arterial tree are fairly common. These arteries have

multiple and plexiform sources; display a temporal succession of the emergence of principal arteries, anastomoses and periarticular networks; and some paths that are initially functionally dominant,

subsequently regress. In general, anomalous patterns may present as differences in the mode and proximodistal level of branching; the presence of unusual compound arterial segments; aberrant vessels that connect with other principal vessels, arcades or plexuses; vessels that occupy exceptional tissue planes or which have unexpected neural, mycological or osteoligamentous relationships[8,9].

Patnaik, Kalsey, Singla[4] (2002) conducted the study on 50 upper limbs of 25 cadavers. The brachial artery was a continuation of axillary artery at lower border of teres major in most cases (98%). But in one case (2%) axillary artery in its third part lies 3 cm proximal to lower border of teres major bifurcated into superficial and deep branches which in the forearm continued as radial and ulnar arteries respectively. Bidarkotimath, Avadhani, Kumar[10] (2011) observed in all 50 cadavers, the brachial artery as a continuation of axillary artery at the lower border of teres major muscle. In present study, all 35 cadavers have the brachial artery as a continuation of the axillary artery.

Luzsa[2] (1974) quoted that the length of the brachial artery vary with the site of division and measures 15 to 30 cm. Patnaik, Kalsey, Singla[4] (2002) in their observation found that total length of the brachial artery being on an average 26.29 cm (ranging from 20.5 to 29.0 cm). Bidarkotimath, Avadhani, Kumar^[10] (2011) measured the length of the brachial artery in male right and left upper limb was 23 ± 8.64 cm and in female right and left upper limb was 22.65 ± 0.77 cm. In present study, the length of brachial artery is found to be 24.91 ± 4.13 cm on right side and 25.27 ± 3.79 cm on left side and smaller length of the artery is also found in the cases of higher termination of the brachial artery.

Luzsa[2] (1974) quoted that the diameter of the brachial artery lies between 0.5-0.6cm. In present study, diameter is taken at origin and above termination. At origin diameter is 0.54 ± 0.06 cm on right side and 0.52 ± 0.05 cm on left side. Above termination diameter is 0.50 ± 0.06 cm on right side and 0.49 ± 0.06 cm on left side.

Patnaik, Kalsey, Singla[4] (2002) observed that mean distance of termination of the brachial artery below intercondylar line is 2.99 cm (ranging from 1.0 to 4.5 cm) in most cases (98%). In one case they found abnormal origin of the brachial artery. In that case axillary artery in its third part lies 3 cm proximal to lower border of teres major bifurcated into superficial and deep branches which in the forearm continued as radial and ulnar arteries respectively. Pulei A, Obimbo M, Ongeti K et al[11] (2012) performed cadaveric dissection in 162 upper limbs. They found

that the brachial artery terminated at the radial neck in 79%, radial tuberosity in 8.6%, proximal arm in 11.1% and mid arm in 1.2% cases. Pattern of termination was either a bifurcation into the radial and ulnar arteries in 90.1% or trifurcation into radial, ulnar and common interosseous arteries in 9.3% cases. They also reported a case of trifurcation of the brachial artery into the profunda brachii, radial and ulnar arteries in 0.6% cases. In present study, termination of the brachial artery below the intercondylar line is seen in 94.28% cases on right side and 97.14% cases on left side with mean distance of 1.18cm (Range 1-1.4cms) on right side and 1.17cm (Range 1-1.4cms) on left side. Brachial artery termination above the intercondylar line is seen in 5.71% cases on right side and in 2.85% cases on left side and these cases were that of the higher termination of the brachial artery.

Rodriguez-Baeza A, Nebot J, Ferreria B et al^[12] (1995) performed total 150 routine dissections of the upper limb from adult cadavers and 10 from full-term fetuses. In 4 cases (2.5%), two brachial arteries were present, one superficial and another deep to the median nerve. In 2 of those cases the superficial brachial artery ended in an anastomosis at the cubital fossa, whereas in the other 2 cases it continued to the antebrachial region. Rodriguez-Niedenfuhr M, Vazquez T, Nearn L et al[13] (2001) examined total of 192 embalmed cadavers (384 upper limbs) 91 males and 101 females. Superficial brachial artery was seen in 4.9% cases (11% male, 7.9% female). Accessory brachial artery was noted in 0.26% cases (1.1% male). Patnaik, Kalsey, Singla[4] (2002) noted double brachial artery i.e. superficial and deep in 2% cases. Superficial brachial artery was seen in 2% cases. Trifurcation of the brachial artery was also seen in 2% cases. Pulei A, Obimbo M, Ongeti K et al^[11] (2012) performed cadaveric dissection in 162 upper limbs in the Department of Anatomy, University of Nairobi, Kenya. They noted superficial brachial artery in 6.1% cases. Higher division was seen in 1.2% cases (in it bifurcation of the brachial artery into radial and ulnar artery was seen in 90.1%, trifurcation into radial, ulnar, common interosseous artery in 9.3% and trifurcation into radial, ulnar, profunda brachii artery in 0.6% cases). Gujar SM, Oza SG, Shekhawat JP et al[14] (2014) has done the study on 30 cadavers in department of anatomy to find out any variations in division pattern of the brachial artery. Variations were found in two cadavers. An unusual short segment of the brachial artery which divide at middle of arm was found in right upper limb of one cadaver. There was a high origin of the radial artery from axillary artery found in right upper limb of one cadaver. Study was done by Ashwini C, Kuberappa V[15] (2014) on

50 cadaveric specimens out of which 49 showed the normal brachial artery configuration. In one cadaver the course of the brachial artery was anomalous. It showed an unusual tortuous course with loops and bends. Tortuous peripheral arteries are usually asymptomatic. An abnormal superficial tortuous brachial artery and its branches may be mistaken for basilic vein during cannulation. Brachial artery aneurysms are rare but potentially limb threatening conditions are also noted by some authors.[16]

In present study, we noted the superficial brachial artery in 8.57% cases on right side and 5.71% cases on left side. Higher termination by bifurcating into radial and ulnar artery is seen in 5.7% cases on right side and 2.85% cases on left side. Accessory brachial artery is seen in 2.85% cases only on right side.

Conclusion

Anatomical knowledge of the brachial artery and variations in them is important because these arteries are most commonly used for procedures like microsurgeries, coronary artery grafting and performing the transarterial coronary procedures. Lack of awareness about variations in the arteries can mislead the surgeon, radiologist, physician while performing various surgeries, radiological procedures and making diagnosis which can affect the proper treatment or can produce the spot emergencies.

References

- Sinnatamby CS. Vessels and nerves of the arm. In: Last's Anatomy, Regional and Applied. 11th edition. Churchill Livingstone; 2006: 61.
- Luzsa G. X-ray Anatomy of the vascular system. Butterworths & Co. (Publishers) Ltd.; Blood vessels of the upper extremities. 1974; 200-207.
- Hollinshead WH. Anatomy for Surgeons: Volume 3. The Back and Limbs. 3rd edition. Philadelphia: Harper and Row Publishers; Chapter 5, Arm, Elbow and Forearm. 1982; 359-364.
- Patnaik VVG, Kalsey G, Singla RK. Branching pattern of Brachial artery- A Morphological study. Journal of Anatomical Society of India. 2002; 51(2): 176-86.
- Ramanathan L, Nayak SR, Vinay KV, Krishnamurthy A, Prabhu LV. Co-existence of superficial brachio-ulno-radial arterial pattern and persistent median artery. Indian Journal of Plastic Surgery. 2009; 42(1): 112-14.
- Bianchini E, Faita F, Gemignani V, Giannoni M, Demi M. The assessment of Flow-Mediated Dilation (FMD) of the brachial artery. Computers in Cardiology. 2006; 33: 509-12.
- Romanes GJ. The arm. In: Cunningham's manual of practical anatomy; Volume 1, Upper and Lower limbs. 15th edition. Oxford University Press; 2003: 67-68, 74-77.
- Standring S (editor-in-chief) et al. Vascular supply and lymphatic drainage. In: Gray's Anatomy. The Anatomical Basis of Clinical Practice. 40th edition. Churchill Livingstone Elsevier; 2008: 827-828, 852-853.
- Moore KL, Persaud TVN. Blood supply of limbs. The Developing Human, Clinically oriented Embryology. 7th edition. Elsevier; Chapter 17, The Limbs. 2005; 412-414.
- Bidarkotimath S, Avadhani R, Kumar A. Primary pattern of arteries of upper limb with relevance of their variations. International Journal of Morphology. 2011; 29(4): 1422-28.
- Pulei A, Obimbo M, Ongeti K, Kitunguu P, Inyimili M, Ogengo J. Surgical significance of brachial arterial variants in a Kenyan population. Annals of African Surgery. 2012; 9.
- Rodriguez-Baeza A, Nebot J, Ferreria B, Reina F, Perez J, Sanudo JR, Roig M. An anatomical study and ontogenetic explanation of 23 cases with variations in the main pattern of the human brachio-antebrachial arteries. Journal of Anatomy. 1995; 187: 473-79.
- Rodriguez-Niedenfuhr M, Vazquez T, Nearn L, Ferreira B, Parkin I, Sanudo JR. Variations of the arterial pattern in the upper limb revisited: A morphological and statistical study, with a review of the literature. Journal of Anatomy. 2001; 199: 547-66.
- Gujar SM, Oza SG, Shekhawat JP, Vikani SK, Prajapati SB. A study on division of brachial Artery and its clinical correlations. Int J Anat Res 2014; 2(1): 208-12.
- Ashwini C, Kuberappa V. An unusual tortuous brachial artery and its branches: histological basis and its clinical perspective. Int. J. LifeSc. Bt & Pharm. Res. 2014; 3(2): 121-4.
- Heydari F, Taheri M, Esmailian M. Brachial artery aneurysm as a limb threatening condition; a case report. Emergency. 2015; 3(2): 75-7.